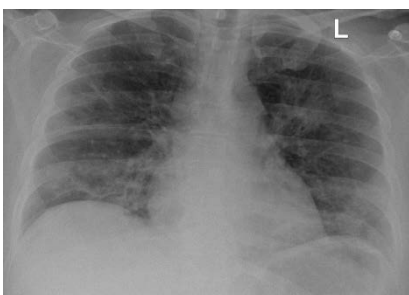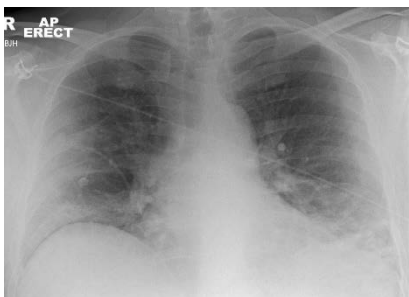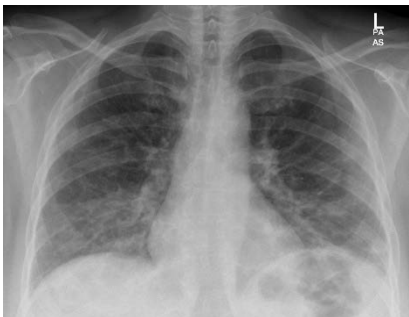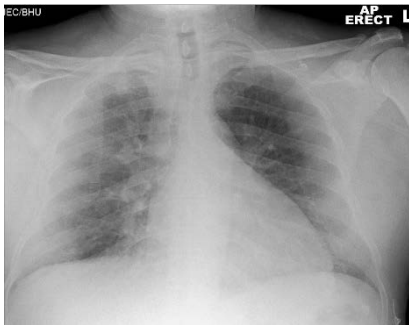


These cases came through the Emergency department of the Imperial College Healthcare NHS Trust over a weekend in late March 2020, and have been classified as mild, moderate or severe. Remember that in a COVID-19 pandemic, changes that you might previously called eosinophilic pneumonia or organising pneumonia are more likely to be COVID-19 because of the disease prevalence.

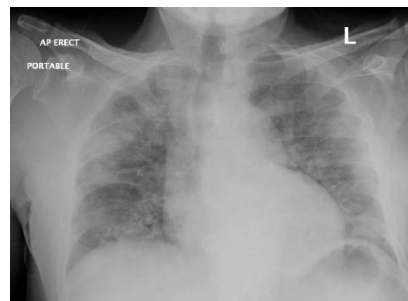
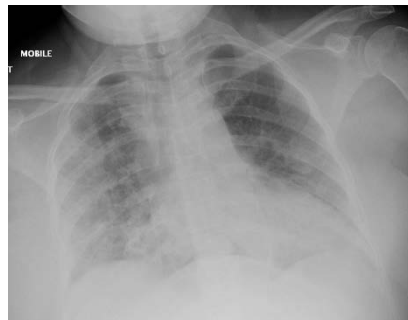
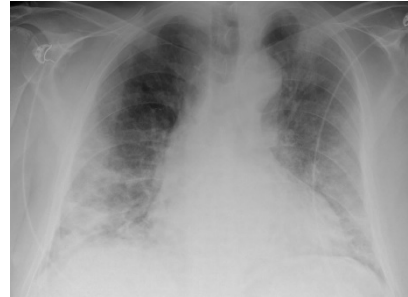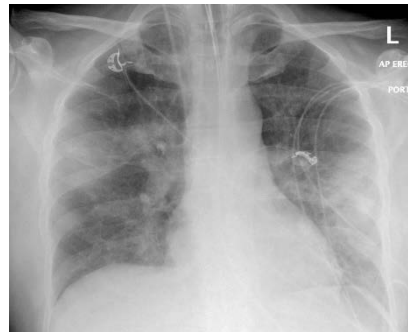
Mild

More black than white



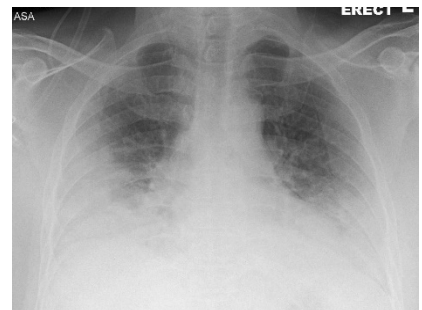
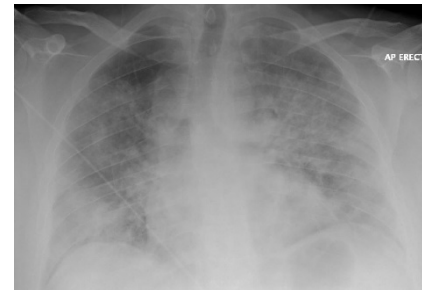
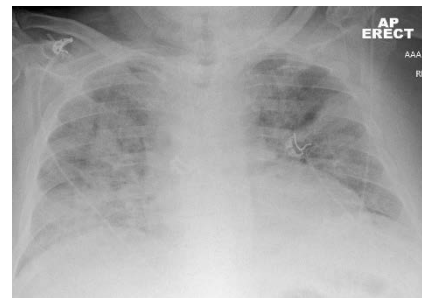
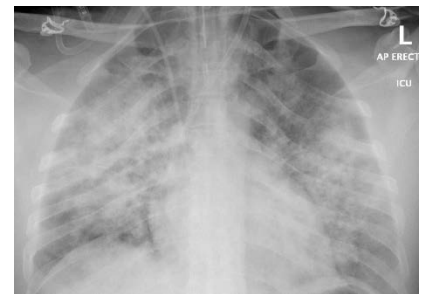Moderate

Equal black and white



Severe

More white than black



These images are taken from a presentation by Dr Mary Roddie, Consultant Thoracic Radiologist at ICHNT, given on 3 April 2020. To view the whole presentation please [click here](#).